

Surgical Intervention in Hyperhidrosis

Kreyden OP, Böni R, Burg G (eds): Hyperhidrosis and Botulinum Toxin in Dermatology. Curr Probl Dermatol. Basel, Karger, 2002, vol 30, pp 57-63

..... **Axillary Sweat Gland Excision**

Jürg Hafner^a, Gertrude M. Beer^b

^a Department of Dermatology and ^b Clinic for Hand, Plastic and Reconstructive Surgery, University Hospital of Zurich, Switzerland

In the axilla, two types of sweat glands can be distinguished – eccrine and apocrine [1]. The eccrine glands produce an aqueous secretion that contains 0.3–0.5% NaCl, potassium, urea and lactic acid. The apocrine glands secrete an odorous fatty fluid. In case of hyperfunction, the eccrine glands are mainly responsible for hyperhidrosis. Excessive apocrine sweat is metabolized by overgrowing corynebacteria which results in malodorous bromhidrosis. The pathophysiology of excessive sweat production is explained in detail elsewhere in this book. Both eccrine and apocrine sweat glands are predominantly located in the superficial subcutis and the dermal-subcutaneous interface. Some additional eccrine glands are completely located in the dermis. It is important to appreciate this anatomical situation, since abrasive surgery such as curettage will not completely remove the dermal sweat glands. Ultimately, excision of axillary skin and subcutaneous tissue en bloc represents the only comprehensive solution for severe *axillary hyperhidrosis*. For the treatment of *bromhidrosis*, it is sufficient to remove the subcutaneous axillary tissue with the subdermally localized apocrine glands.

Nevertheless, a step-wise approach is commonly recommended for the treatment of excessive axillary sweating. Mild to moderate hyperhidrosis can be controlled with aluminium chloride hexahydrate in a 20–30% solution [2, 3]. Water iontophoresis is less convenient for the axillae, since it may cause considerable irritation in this location [4]. Botulinum toxin A has become a popular treatment for axillary hyperhidrosis. It is highly effective; however, the costly sessions have to be repeated every few months. Botulinum toxin A is discussed in detail elsewhere in this book.

Surgical procedures are generally reserved for the severest cases of axillary hyperhidrosis. *Endoscopic thoracic sympathectomy* is typically used for treating

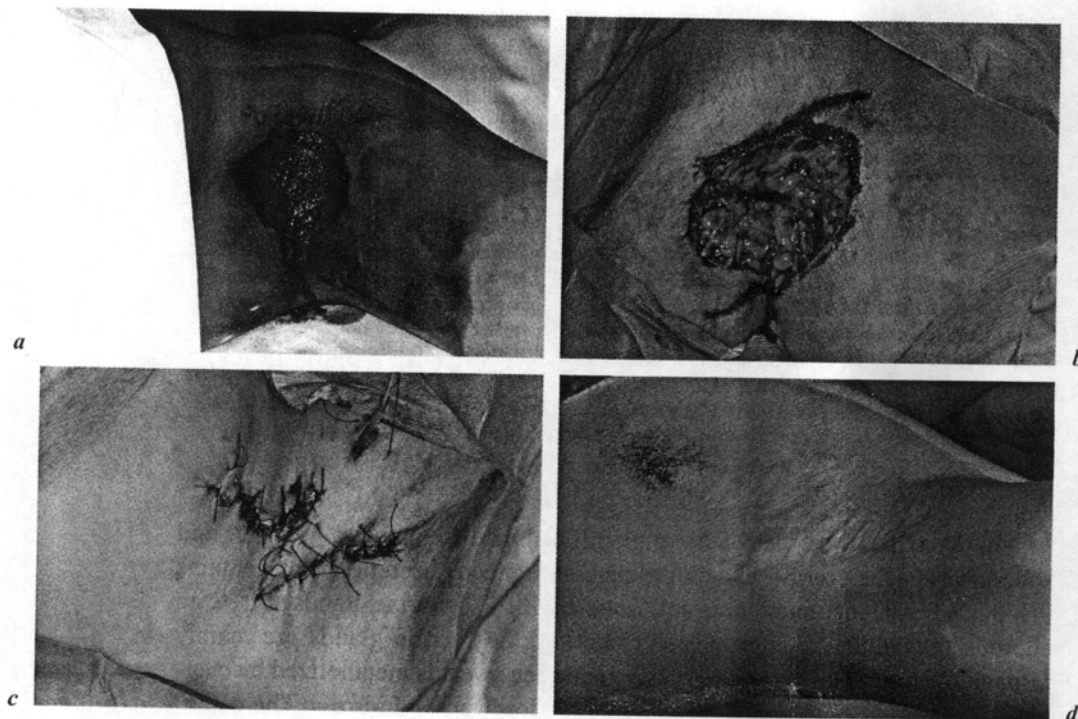


Fig. 1. *a* Iodine-starch test. *b* Radical sweat gland excision: intraoperative view. *c* Z-plasty. *d* Postoperative result at 1 year: broad, z-shaped scar, cessation of hyperhidrosis.

severe combined palmar and axillary hyperhidrosis at the same time. Satisfaction rates (total satisfaction) reach 87% for the palms and 68% for the axillae [5]. Axillary sweat gland excision on the other hand – an outpatient intervention under tumescent local anesthesia – represents a relatively simple and highly effective option for isolated axillary hyperhidrosis, without concomitant palmar hyperhidrosis. According to the different methods used (see below), satisfaction rates range between 50 and 95% [6].

The apocrine sweat glands are confined to the hair-bearing area of the axillae, whereas the eccrine glands can be found outside this area. The iodine-starch test is a suitable procedure to delineate the hyperhidrotic area. After cleansing the axilla, an aqueous 2% iodine solution is applied with a swab and dried again with a cotton gauze so that most of the yellow solution concentrates at the excretory ducts of the sweat glands. After the application of starch powder to the hyperhidrotic area, the iodine solution turns intensely black (fig. 1a).

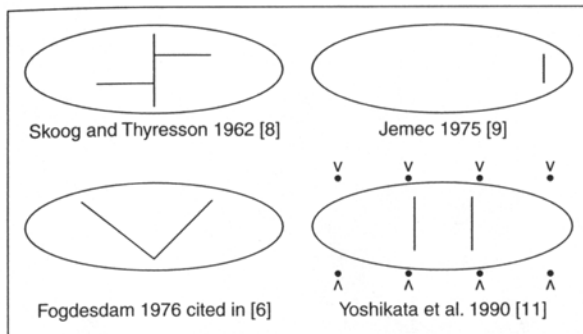


Fig. 2. Several examples of incision of axillary skin and removal of subcutaneous glandular tissue. ○ = Hyperhidrotic area.

Surgical Procedures

Axillary sweat gland excision is performed with the arm positioned at a 90-degree angle. Tumescent local anesthesia is commonly used. Due to the topography of eccrine and apocrine sweat glands and the interplay of hyperhidrosis and bromhidrosis, a myriad of procedures has been described, which can be roughly classified into one of three groups [6, 7].

Incision of Skin and Removal of Subcutaneous Sweat Glands

The abrasive methods, which are outlined in figure 2 [8–11], use a small incision to remove the subdermal sweat glands and the subcutaneous fat down to the level of the superficial axillary fascia. Attention should be paid to the intercostobrachial nerves. Since the excretory ducts of the sweat glands adhere strongly to the dermis, they have to be separated with a scalpel or a sharp curette. If the subdermal vascular plexus gets damaged during this procedure, the remaining skin should be treated as if it was a full-thickness skin graft and fixed with a tie-over bandage [11]. All these procedures require meticulous hemostasis and a 24-hour drainage is recommended (fig. 3a–e). Due to the known, limited radicality, the satisfaction rate of this type of procedure varies greatly from 50 to 95% [8–12]. The cosmetic result, however, is generally judged very good, since it leaves very acceptable, small scars.

This type I surgical approach is predominantly recommended for the treatment of bromhidrosis. For the severest kinds of hyperhidrosis and for the combined treatment of hyperhidrosis and bromhidrosis, type II would be the surgical approach of choice.

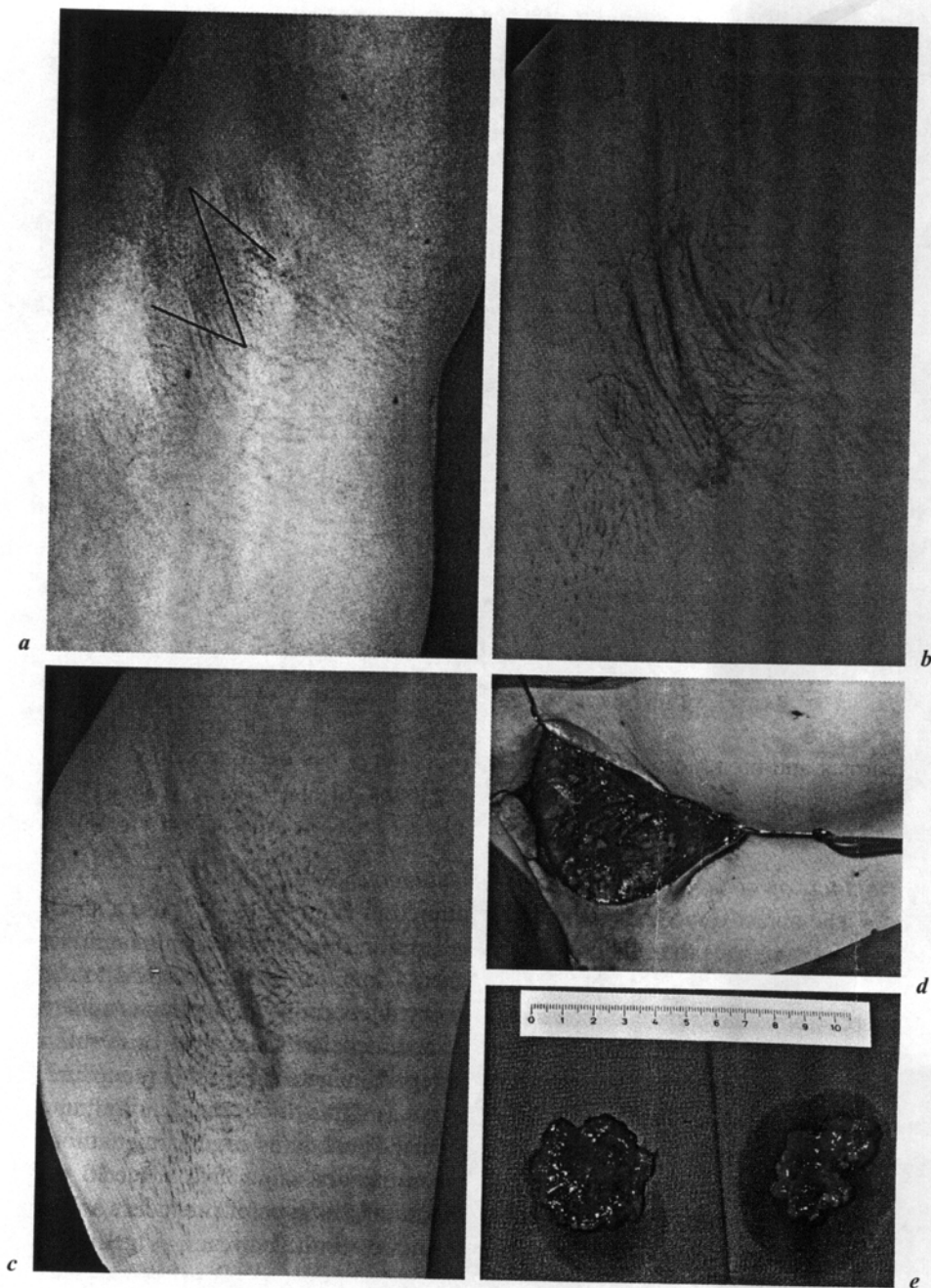


Fig. 3. *a* Preoperative marking of skin incision. *b* Postoperative result at 1 month: z-scar still noticeable (red). *c* Postoperative result at 6 months: z-scar hardly noticeable. *d* Intraoperative view of undermining, note the intercostobrachial nerve. *e* Subcutaneous glands resected en bloc.

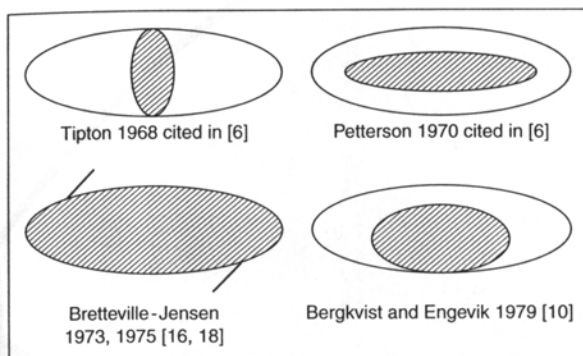


Fig. 4. Excision of skin and subcutaneous tissue en bloc (radical sweat gland excision). Several subtotal and one radical procedures. \bigcirc = Hyperhidrotic area; shaded oval = area excised.

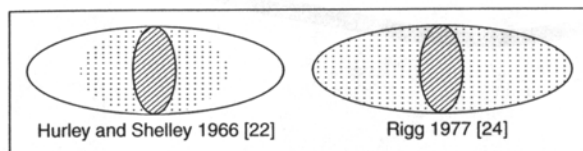


Fig. 5. Limited excision of skin and removal of surrounding subcutaneous sweat glands. \bigcirc = Hyperhidrotic area; shaded oval = area excised; dashed oval = area undermined.

Excision of Skin and Subcutaneous Tissue en bloc (Radical Sweat Gland Excision)

Several reconstructive surgical methods for radical sweat gland resection are summarized in figure 4 [6, 7, 10, 13–21]. Several authors suggested either a transverse or longitudinal elliptic resection of the skin and subcutaneous tissue in the axillary cavity, where the density of eccrine sweat glands is the highest (area of approx. 2×5 cm). Others have preferred to excise the complete hyperhidrotic area according to the iodine-starch test (approx. 5×8 cm). At our institution we usually perform a large longitudinal elliptic excision including the complete hyperhidrotic area and a z-plasty repair, as suggested by Bretteville-Jensen [18, 19] (fig. 1a–d). The latter method yields very high long-term success rates (90–95%). The main drawback is a large and dehiscent z-shaped scar in the axilla.

Limited Excision of Skin and Removal of Surrounding Subcutaneous Sweat Glands

As a compromise between radical excision of a large area of skin or curettage through a 'key hole', several authors have suggested to combine a central excision of skin and curettage in the periphery (fig. 5) [6, 13, 22–24].

A limited ellipse of skin of approximately 2×5 cm is excised in the cavity of the axilla. The periphery is undermined and the remaining sweat glands there are dissected off the adjacent skin. This type of procedure usually results in high patient satisfaction and acceptable scars.

Conclusion

Sweat gland excision represents a relatively simple and highly effective treatment for recalcitrant axillary hyperhidrosis as well as bromhidrosis. It can be safely performed under tumescent local anesthesia. Purely abrasive methods without skin excision yield very good aesthetic results; however, long-term functional results are less predictable.

The radical elliptic resection of the entire hyperhidrotic area is particularly effective, but ultimately it may result in a broad, z-shaped scar.

As a compromise, interventions that combine a limited radical sweat gland excision in the axillary cavity with curettage of the peripheral glands effectively stop hyperhidrosis and result in a cosmetically acceptable scar.

References

- 1 Bang YH, Kim JH, Paik SW, Park SW, Jackson IT, Lebeda R: Histopathology of apocrine bromhidrosis. *Plast Reconstr Surg* 1996;98:288-292.
- 2 Graber W: Eine einfache, wirksame Behandlung der axillären Hyperhidrose. *Schweiz Rundsch Med (Praxis)* 1977;66:1080-1084.
- 3 Glent-Madsen L, Dahl JC: Axillary hyperhidrosis: Local treatment with aluminium-chloride hexahydrate 25% in absolute ethanol with and without supplementary treatment with triethanolamine. *Acta Derm Venereol (Stockh)* 1988;68:87-89.
- 4 Hölzle E, Ruzicka T: Treatment of hyperhidrosis by a battery-operated iontophoretic device. *Dermatologica* 1986;172:41-47.
- 5 Rex LO, Drott C, Claes G, Göthberg G, Dalman P: The Boras experience of endoscopic thoracic sympathectomy for palmar, axillary, facial hyperhidrosis and facial blushing. *Eur J Surg* 1998; suppl 580:23-26.
- 6 Bisbal J, del Cacho C, Casalots J: Surgical treatment of axillary hyperhidrosis. *Ann Plast Surg* 1987;18:429-435.
- 7 Wu WH, Ma S, Lin JT, Tang YW, Fang RH, Yeh FL: Surgical treatment of axillary osmidrosis: An analysis of 343 cases. *Plast Reconstr Surg* 1994;94:288-294.
- 8 Skoog T, Thyresson N: Hyperhidrosis of the axillae: A method for surgical treatment. *Acta Chir Scand* 1962;124:531-538.
- 9 Jemec B: Abrasio axillae in hyperhidrosis. *Scand J Plast Surg* 1975;9:44-46.
- 10 Bergkvist L, Engevik L: The surgical treatment of axillary hyperhidrosis. *Br J Surg* 1979;66:482-484.
- 11 Yoshikata R, Yanai A, Takei R, Shionome H: Surgical treatment of axillary osmidrosis. *Br J Plast Surg* 1990;43:483-485.
- 12 Ellis H: Axillary hyperhidrosis: Failure of subcutaneous curettage. *Br Med J* 1977;30:301-302.
- 13 Hurley HJ, Shelley WB: A simple surgical approach to the management of axillary hyperhidrosis. *JAMA* 1963;186:109-112.

- 14 Préaux MJ: Le traitement chirurgical de l'hyperhidrose axillaire. *Bull Soc Fr Dermatol Syphiligr* 1967;74:730-733.
- 15 Davis PKB: Surgical treatment of axillary hyperhidrosis. *Br J Plast Surg* 1971;24:99-100.
- 16 Bretteville-Jensen G: Radical sweat gland ablation for axillary hyperhidrosis. *Br J Plast Surg* 1973;26:158-162.
- 17 Munro DD, Verbov JL, O'Gorman DJ, du Vivier A: Axillary hyperhidrosis. *Br J Dermatol* 1974;90:325-329.
- 18 Bretteville-Jensen G, Mossing N, Albrechtsen R: Surgical treatment of axillary hyperhidrosis in 123 patients. *Acta Derm Venereol (Stockholm)* 1975;55:73-77.
- 19 Eichmann A, Ott F, Scherrer A: Eine operative Therapie der Hyperhidrosis axillaris. *Schw Rundsch Med (Praxis)* 1977;66:609-612.
- 20 Hill TG: Radical excision and reconstruction of axillary skin. *Dermatol Surg* 1983;9:299-303.
- 21 Stenquist B: Axillary hyperhidrosis: A simple surgical procedure. *Dermatol Surg* 1985;11:388-391.
- 22 Hurley HJ, Shelley WB: Axillary hyperhidrosis. *Br J Dermatol* 1966;78:127-140.
- 23 Weaver PC: Axillary hyperhidrosis. *Br Med J* 1970;i:48.
- 24 Rigg BM: Axillary hyperhidrosis. *Plast Reconstr Surg* 1977;59:334-342.

Jürg Hafner, MD, Department of Dermatology, University Hospital of Zurich,
CH-8091 Zurich (Switzerland)
Tel. +41 1 255 34 45, Fax +41 1 255 44 03, E-Mail jhafner@derm.unizh.ch