

## Structural changes in axillary eccrine glands following long-term treatment with aluminium chloride hexahydrate solution

E.HÖLZLE\* AND O.BRAUN-FALCO†

\* Department of Dermatology, University of Düsseldorf and † Department of Dermatology, University of Munich

Accepted for publication 4 October 1983

### SUMMARY

Axillary skin biopsies from fifteen patients with axillary hyperhidrosis who had received long-term treatment with aqueous aluminium chloride solution were examined histologically. The apocrine glands were normal, but the eccrine glands showed conspicuous morphological changes of varying severity. These included vacuolization of the secretory epithelium, dilatation of eccrine acini with atrophy of secretory cells, and accumulation of PAS-positive, diastase-resistant material in the dilated lumen of the secretory coils. The histological changes correlated in most patients with decreased secretion of sweat. We conclude that long-term blockage of the distal acrosyringium due to aluminium salts may lead to functional and structural degeneration of the eccrine acini.

Aluminium chloride hexahydrate is widely used as the active ingredient in antiperspirant preparations. Its efficacy has been proven (Shelley & Hurley, 1975; Scholes *et al.*, 1978; Bandrup & Larsen, 1978; Hölzle, 1983) and its basic mechanism of action has been established (Reller & Luedders, 1977; Hölzle & Kligman, 1979a; Quatrone *et al.*, 1981). It has been found that aluminium and other metallic compounds with antiperspirant properties cause mechanical obstruction of the eccrine sweat duct within the acrosyringium. Hölzle & Kligman (1979a) suggested that metal ions form precipitating complexes with mucopolysaccharides and cause damage to luminal epithelial cells, thus generating an obstructive conglomerate completely plugging the acrosyringium. The secretory portion of the eccrine gland is not affected primarily by the metallic salt and remains active as is vividly demonstrated by the eruption of miliaria under heat stress in sites rendered anhidrotic by aluminium chloride solution.

Since patency of the epidermal sweat duct is restored by renewal of the acrosyringium due to epidermopoiesis, treatment of hyperhidrosis requires repeated exposures to aluminium

chloride for prolonged periods of time. We have monitored a large group of axillary hyperhidrotics during long-term treatment with aluminium chloride solutions (Hölzle, 1983). The severity of hyperhidrosis seemed to decrease during the treatment period and this was reflected by a marked decrease in the frequency of treatments required to control the hyperhidrosis. This observation suggested that long-term application of aluminium salt solutions might alter the secretory portion of the eccrine glands functionally or structurally.

The present study was designed to investigate possible structural changes in axillary eccrine glands due to long-term aluminium chloride applications.

#### METHODS

Out of a group of 158 patients treated for axillary hyperhidrosis fifteen patients were arbitrarily selected for histological examination. These were seven females and eight males aged 24 to 60 years (mean 39.7). The only precondition for entering the study was that the patient had successfully treated the hyperhidrotic condition for at least 6 months before study. Hyperhidrosis was treated by overnight applications of 15% or 20% aluminium chloride hexahydrate in 2% methylcellulose as described previously (Hölzle, 1983). Individual treatment schedules varied from thrice weekly to applications once every 2 to 3 weeks (mean every 6.5 days). Treatment periods ranged from 6 to 40 months (mean  $26.5 \pm 12.5$ ).

Small elliptical skin excisions about 1.5 cm in length were performed under local anaesthesia. All biopsies were taken from the lateral periphery of the axillary vault but still within the hair bearing area. Skin specimens were formalin-fixed, embedded in paraffin, serially sectioned and stained with haematoxylin-eosin and PAS.

Ten patients in whom excision of axillary skin for surgical treatment of hyperhidrosis was performed served as controls. Skin specimens were processed histologically as described above.

#### RESULTS

*Controls.* In all control patients who had not received aluminium chloride the axillary eccrine glands appeared normal. Very rarely, the lumina of acini and dermal ducts seemed to be slightly dilated.

*Effects of aluminium chloride.* The apocrine glands were found to be unchanged in all patients examined.

Within the acrosyringium of eccrine glands the characteristic plugs were found accompanied by necrosis of epidermal cells lining the ducts. Rupture of dermal or epidermal eccrine ducts was not observed. Apart from these acute effects of aluminium chloride on the distal portion of the glands, pronounced structural alterations of the eccrine acini were to be seen.

Subtle structural alterations which could be discerned were widening of the lumina of eccrine acini and dermal ducts and vacuolization of secretory cells (Fig. 1). The clear vacuoles were intra- as well as intercellular. As these changes became more prominent more eccrine glands were involved. The extent of structural alterations varied in one given skin specimen among different eccrine units. As damage increased, dilation of the secretory portion became more conspicuous and the acini appeared irregular and seemed to lose their structural integrity. Secretory cells appeared to undergo atrophy.

In severely altered eccrine glands the acini were grossly dilated and the secretory epithelium formed a thin layer which appeared stretched and atrophic. Some acini were filled with a

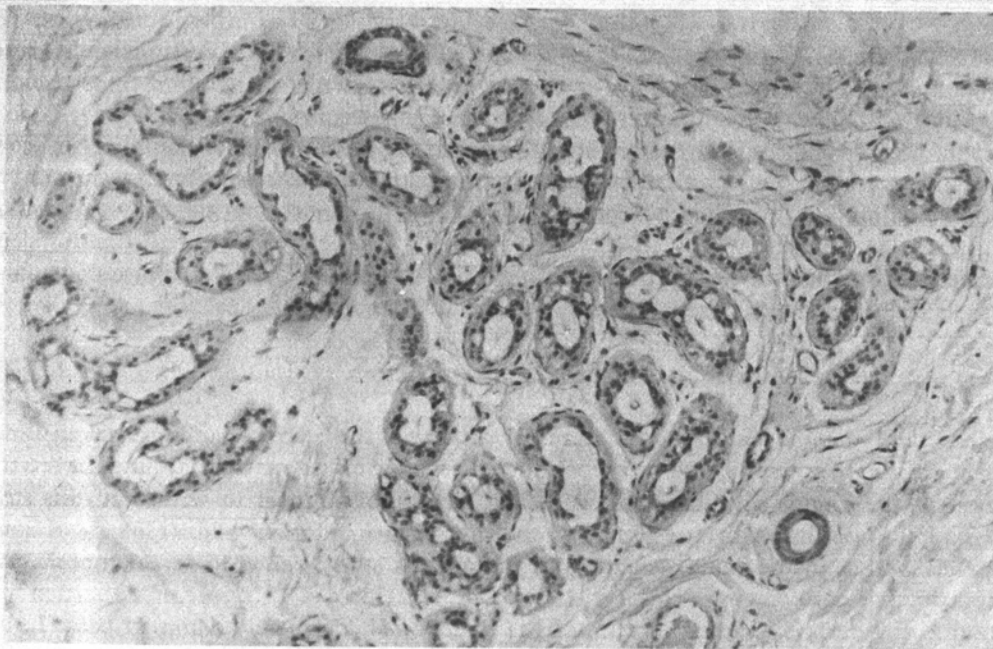


FIGURE 1. Eccrine acini showing vacuolization of the secretory epithelium and irregularly dilated lumina (H & E,  $\times 115$ ).

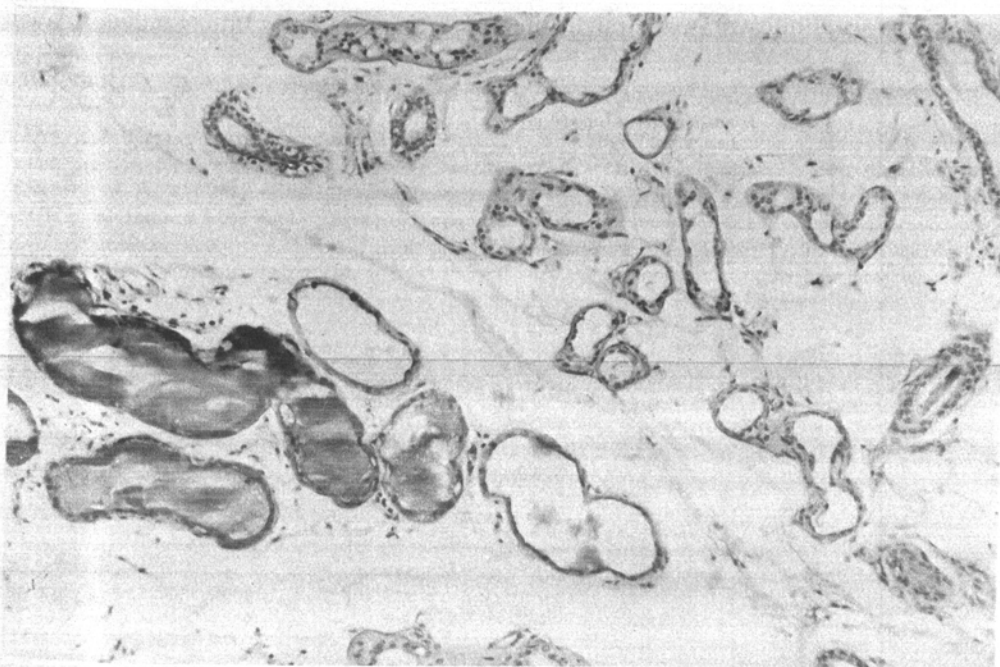


FIGURE 2. Grossly dilated and atrophic acini filled with PAS-positive material next to moderately affected eccrine gland (H & E,  $\times 115$ ).

PAS-positive, diastase-resistant, amorphous material (Fig. 2). In this stage, the eccrine secretory portions resembled apocrine acini depleted of their secretion. Again, glands were not equally affected. In most specimens, beside severely altered glands, moderately changed and sometimes normal eccrine units were detected.

A synopsis of the data is given in Table 1. Among the fifteen patients examined six showed severe disintegration of glandular structures, in four patients moderate changes were found and in the remaining five individuals only mild alterations of eccrine glands were seen. No correlation was found between the severity of the histological changes and the duration of treatment. Also the amelioration of hyperhidrosis as reflected by the increase of treatment intervals did not seem to be closely related to the structural changes seen histologically.

#### DISCUSSION

It is generally thought that the active secretory process of the eccrine glands creates an osmotic pressure of 300 to 500 mmHg. The myoepithelial cells forming a network around the secretory portion of the glands give the acini sufficient structural support to withstand this strain. Experimental anhidrosis due to aluminium chloride on back or forearm skin (Hölzle & Kligman, 1979a) as well as in the axilla, as shown in the present study, failed to reveal rupture of the eccrine ducts. Therefore, it must be concluded that sweat formed by the secretory portion either leaks into the dermis without rupture of the ducts or is completely dammed back. In both instances the intraluminal hydrostatic pressure will rise and it seems that the secretory portion cannot withstand the increased pressure over sustained periods of time. Apparently, chronic sweat retention finally leads to dilation and atrophy of the eccrine acini with loss of secretory function.

However, susceptibility to structural disintegration seems to differ among individuals as well

TABLE 1. Synopsis of experimental and histological findings during long-term treatment with topical aluminium chloride hexahydrate

Patient sex and age	Duration of treatment (months)	Treatment intervals at beginning/end of treatment (days)	Degree of structural alteration of eccrine acini
F, 36	40	3/10	++
F, 38	39	2-3/21	+
F, 45	39	2-3/10	+++
M, 24	38	4/7	+
F, 37	36	4-5/4-5	+++
M, 40	36	3-4/14	++
F, 46	36	3-4/14	+
F, 52	29	5/5	++
F, 41	24	2-3/4-5	+++
M, 26	23	2-3/14	+++
M, 31	18	2/3-4	+++
M, 46	18	2-3/5-6	+++
M, 35	10	7/7	+
M, 39	6	2-3/14-21	++
M, 60	6	2-3/7	+

as in various probably a treatment

It is not salts and se generating ducts remain aluminium injection of Although long-term understood necessary.

The technique acknowledged

BANDRUP, F. & K. (1979) 25% in at  
 HÖLZLE, E. (1979) by O. Braun-Falco  
 HÖLZLE, E. & J. Kligman (1979) *Cosmetic Clinician*  
 HÖLZLE, E. & J. Kligman (1979) *Investigative Dermatology*  
 QUATRALE, R. J. (1979) aluminium chloride hexahydrate *Journal of the American Academy of Dermatology*  
 RELLER, H. H. (1979) sweat gland disease *H.I. Maibach's Dermatology*  
 SCHOLES, I. T. (1979) alcoholic skin disease *Sherlock's Dermatology*  
 SHELLEY, W. B. (1979) *Dermatology*

as in various glands within a given patient. This heterogeneity in the resistance of eccrine acini probably accounts for the failure to correlate the degree of structural alterations with duration of treatment or with reduction of sweat rates as therapy is continued over longer periods.

It is not surprising that apocrine axillary glands were not altered by aluminium salts. Metallic salts and some other water-soluble irritants selectively damage the eccrine acrosyringium, thus generating an occlusive plug in the distal eccrine ducts (Hölze & Kligman, 1979b). The apocrine ducts remain patent. Even when complete anhidrosis is induced in the axilla by use of aluminium chloride solution one can observe secretion of apocrine sweat upon intradermal injection of adrenalin (unpublished observation).

Although hyperhidrotic patients are pleased to find their condition improving during long-term treatment, the consequences of the present findings are not yet completely understood. Further studies on the kinetics and reversibility of the observed changes are necessary.

## ACKNOWLEDGMENT

The technical assistance of Mrs R. Simon in preparing the histological specimens is gratefully acknowledged.

## REFERENCES

- BANDRUP, F. & LARSEN, P.O. (1978) Axillary hyperhidrosis. Local treatment with aluminium chloride hexahydrate 25% in absolute ethanol. *Acta Dermato-venereologica (Stockholm)*, **58**, 461.
- HÖLZE, E. (1983) Hyperhidrosis-Therapie. In: *Fortschritte der praktischen Dermatologie und Venerologie*. Band 10 (Ed. by O. Braun-Falco and G. Burg), p. 191. Springer Verlag, Berlin.
- HÖLZE, E. & KLIGMAN, A.M. (1979a) Mechanism of anti-perspirant action of aluminum salts. *Journal of the Society of Cosmetic Chemists*, **30**, 279.
- HÖLZE, E. & KLIGMAN, A.M. (1979b) Selective damage of the acrosyringium by water-soluble irritants. *Journal of Investigative Dermatology*, **72**, 276.
- QUATRALE, R.P., COBLE, D.W., STONER, K.L. & FELGER, C.B. (1981) The mechanism of antiperspirant action by aluminum salts. II. Histological observations of human eccrine sweat glands inhibited by aluminum chlorohydrate. *Journal of the Society of Cosmetic Chemists*, **32**, 107.
- RELLER, H.H. & LUEDDERS, W.L. (1977) Pharmacologic and toxicologic effects of topically applied agents on the eccrine sweat glands. In: *Advances in Modern Toxicology, Dermatotoxicology and Pharmacology* (Ed. by F.N. Marzulli and H.I. Maibach), Vol. 4, p. 18. Hemisphere Publishing Co., Washington, London.
- SCHOLES, I.T., CROW, K.D., ELLIS, J.P., HARMAN, R.R. & SAIHAN, E.M. (1978) Axillary hyperhidrosis treated with alcoholic solution of aluminium chloride hexahydrate. *British Medical Journal*, **78**, 84.
- SHELLEY, W.B. & HURLEY, H.J. (1975) Studies on topical antiperspirant control of axillary hyperhidrosis. *Acta Dermato-venereologica (Stockholm)*, **55**, 241.