

Lower Relapse Rate of Botulinum Toxin A Therapy for Axillary Hyperhidrosis by Dose Increase

Theodor Karamfilov, MD; Helga Konrad, MD; Kerstin Karte, MD; Uwe Wollina, MD

Background: Primary focal hyperhidrosis is a common condition that gives rise to functional and emotional problems and may disturb professional and social life. Recently, low-dose intracutaneous injections of botulinum toxin A have been shown to induce a temporary anhidrosis, with relapses occurring usually after 4 to 6 months.

Objective: To evaluate the short- and long-term effectiveness and possible adverse effects of high-dose botulinum toxin therapy in the treatment of axillary hyperhidrosis.

Design: In an open study, patients with focal hyperhidrosis were treated with intracutaneous injections of botulinum toxin A (Botox; Allergan Inc, Irvine, Calif). A total dose of 200 U of botulinum toxin A was used once per axilla. Patients were observed for up to 15 months.

Settings: University medical center.

Patients: Twenty-four patients with axillary hyperhidrosis were treated. Their ages ranged from 19 to 58 years (mean \pm SD, 34.8 \pm 12.4 years).

Main Outcome Measures: Reduction of sweating as assessed by the Minor iodine-starch test and planimetry of hyperhidrotic areas. Patients were interviewed at the end of follow-up about their satisfaction with this treatment.

Results: Within 6 days, all patients reported cessation of excessive sweating. The mean \pm SD area of excessive sweating identified by the Minor iodine-starch test decreased from 19.27 \pm 11.95 cm² to 0.25 \pm 0.61 cm² ($P < .001$). The mean follow-up was 10.0 \pm 2.8 months (range, 5-15 months). Four patients (17%) reported a return of axillary hyperhidrosis after 7 to 10 months. All patients who experienced relapse showed an excellent response to a second treatment. The only adverse effects reported were temporary pain and burning during the injections. No muscular weakness, insensitivity, or systemic reactions were observed.

Conclusions: High-dose botulinum toxin A seems to be as safe as low-dose botulinum toxin A in the treatment of axillary hyperhidrosis. The preliminary data suggest a lower rate of relapse.

Arch Dermatol. 2000;136:487-490

P RIMARY HYPERHIDROSIS is a disorder of excessive sweating caused by a dysfunction of the neuroexocrine interplay between the nervous system and eccrine glands. It may cause considerable social, psychological, and occupational problems. Most often, the condition involves the palms, soles, and axillae, where the eccrine sweat glands are concentrated. These glands are innervated by cholinergic fibers from the sympathetic nervous system. Acetylcholine is the most effective sudorific neurotransmitter.¹

*For editorial comment
see page 539*

Botulinum toxin A is one of 7 neurotoxins produced by *Clostridium botulinum* that exert their paralytic activity at the neuromuscular junction by inhibiting the release of acetylcholine. The toxin is syn-

thesized as a single-chain molecule of about 150 kd and modified in a 2-step process. The resulting molecule consists of a light chain acting as a zinc endopeptidase and a heavy chain that provides cholinergic specificity and promotes light-chain translocation across the endosomal membrane of synapses. After internalization of the whole molecule, the disulfide bond is cleaved. The light chain interferes with SNAP-25, a 25-kd synaptosome-associated protein that is involved in acetylcholine release.²

Botulinum toxin A is approved in many countries to treat spasticity, including blepharospasm, but there are several potential new indications.³ There are 2 different preparations on the German market: Botox (Allergan Inc, Irvine, Calif [distributed by Merz & Co, Frankfurt am Main, Germany]) and Dysport (Ipsen Pharma, Rheinbeck, Germany). These 2 preparations are distinct because of dif-

From the Department of Dermatology, the Friedrich Schiller University of Jena, Jena, Germany.

PATIENT AND METHODS

PATIENTS

Twenty-four patients with focal axillary hyperhidrosis that did not respond to other nonsurgical treatments were treated with botulinum toxin A (14 women and 10 men). Their ages ranged from 19 to 58 years (mean \pm SD, 34.8 \pm 12.4 years). All patients had focal hyperhidrosis since childhood. Patients younger than 18 years of age, pregnant women, and patients with symptomatic hyperhidrosis were excluded, as were patients with contraindications listed in the Botox user leaflet. Informed consent was obtained from all patients after full written and oral explanation of the study was provided.

METHODS

All patients underwent a pretreatment evaluation consisting of a clinical examination, objective quantification of sweat production, and photodocumentation of sweat production. Hyperhidrotic areas were evaluated by the Minor iodine-starch test.¹⁵ In this test, 2 g of iodine and 4 g of potassium iodide in 100 mL of alcohol is painted over the skin area. After it dries, a fine starch powder is applied. Sweat causes the starch powder to turn dark blue. In all cases, the iodine-starch test made it very easy to discern the exact location of excess sweating in the axillary skin (**Figure**).

For each axilla, 200 U of botulinum toxin A (Botox) was diluted with 4.0 mL of 0.9% sterile physiological saline without preservative. The toxin was injected in amounts of 0.05 to 0.1 mL (5-10 U) strictly intracutaneously using a 30-gauge needle. For the axillary region, 16 to 32 injections were given. No analgesic therapy was necessary. We started with single-site treatment. Three days after the initial injections, the second axilla was treated the same way.

Patients were reexamined between 5 and 15 months later (mean \pm SD, 10.0 \pm 2.8 months). The Minor iodine-starch test was used to assess the clinical antisudorific activity. In 22 patients, the area of sweating was also assessed by planimetry.

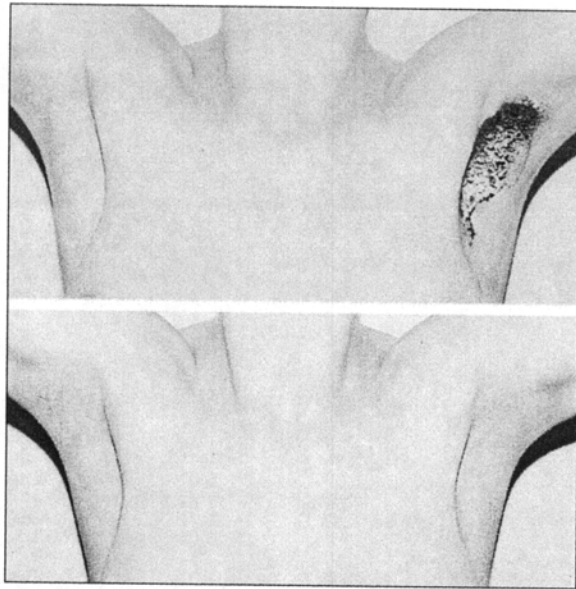
A relapse was defined as a remarkable increase of sweating as experienced by the patient and an increase in hyperhidrotic area greater than 25% as determined by the Minor iodine-starch test.

STATISTICAL ANALYSIS

A paired *t* test was performed to compare the area of excessive sweating (Minor iodine-starch test) as assessed by planimetry before and after treatment. $P < .05$ was considered statistically significant.

ferent vehicles, dilution schemes, and potency testing. Most studies suggest that 1 U of Botox is equivalent to 3 to 5 U of Dysport.²

The use of botulinum toxin A to inhibit hyperhidrosis is based on observations in healthy volunteers performed in the mid-1990s.^{4,5} Preliminary clinical studies



Patient with axillary hyperhidrosis before (top) and 5 days after (bottom) botulinum toxin A therapy. Results of the Minor iodine-starch test showed that hyperhidrosis occurred before and hypohidrosis after treatment.

demonstrated that this toxin can be used both safely and effectively to treat focal hyperhidrosis. The effect is longer lasting than any of the nonsurgical treatments used for focal hyperhidrosis.⁶⁻¹² The major drawback of this treatment is that it must be repeated several times to be effective. Most relapses occur between 4 and 6 months after initial treatment.^{6,11} In previous studies, botulinum toxin A has been used as a low-dose therapy in which 20 to 100 U are applied per area (palm, sole, or axilla). Repeated application may induce specific antibodies that can reduce the efficacy of this treatment by immunoresistance.^{13,14}

In the present study, we investigated the efficacy and safety of high-dose botulinum toxin A in patients with palmar and axillary hyperhidrosis. We also wanted to find out if a higher initial dose would prolong its anhidrotic effect.

RESULTS

Intracutaneous injections of botulinum toxin A were well tolerated by all patients. Mild pain was experienced during the injections. Burning sensations were reported to last up to 1 hour. The development of hematomas was not observed. Allergic or systemic adverse effects did not occur. Muscular power and sensations of the axillary region remained unchanged. None of the patients developed compensatory hyperhidrosis on other parts of the body.

In each of the 24 patients, hyperhidrosis was relieved during the first 6 days, with anhidrotic areas developing at the sites of botulinum toxin A injections. Minor iodine-starch test results showed that each injection produced an area of anhidrosis with a diameter of 1.2 to 1.9 cm. The mean \pm SD pretreatment area of increased sweating was 19.27 \pm 11.95 cm²; posttreatment it was 0.25 \pm 0.61 cm². The difference reached significance ($P < .001$). Four of the 24 patients reported a partial relapse of axillary sweating after 7 ($n = 2$), 8 ($n = 1$), and 10 ($n = 1$)

Review of Botulinum Toxin A Therapy for Focal Hyperhidrosis*

Study	No. of Patients or Healthy Volunteers and Disease	Follow-up	Relapse	Relapse Rate	Areas Treated (No. of Areas Treated)
Bushara et al, ⁵ 1996	7 Healthy volunteers	6-8 mo	Axillary relapses after 6 mo	100% Within 6 mo	Axilla (5) and dorsum of the hand (2)
Cheshire ⁴ 1996	1 Healthy volunteer	Almost 1 y	Forearm
Schnider et al, ⁶ 1997	11 Patients with palmar hyperhidrosis	13 wk	3/11 after 13 wk	23% Within 13 wk	Palms (11)
Glogau, ⁹ 1998	12 Patients with axillary hyperhidrosis	4-7 mo	Relapses after 5 mo	...	Axillae (24)
Heckmann et al, ¹⁰ 1998	6 Patients with axillary hyperhidrosis	3 mo	No relapse	0% Within 3 mo	Axillae (6)
Heckmann et al, ²⁵ 1998	12 Patients with axillary hyperhidrosis	12 mo	Relapses after 3 (n = 1), 4 (n = 1), and 7 (n = 1) mo	25% Within 12 mo	Axillae (12)
Naumann et al, ¹¹ 1998	11 Patients with focal hyperhidrosis	Up to 5 mo	No clinically relevant relapse	0% Clinically relevant within 5 mo	Axillae (16), palms (8), and soles (2)
Naumann et al, ¹² 1998	20 Patients with axillary hyperhidrosis	3-4 wk	Axillae (8) and palms (32)
Shelly et al, ⁸ 1998	4 Patients with palmar hyperhidrosis	12 mo	Relapses after 4 (n = 1), 7 (n = 2), and 12 (n = 1) mo	100% Within 12 mo	Palms (8)
Odderson ²⁶ 1998	2 Patients with axillary hyperhidrosis	4 wk	Relapses after 11 wk (n = 1) and 2 mo (n = 1)	100% Within 2 mo	Axillae (4)
Present study	24 Patients with axillary hyperhidrosis	Up to 15 mo	Relapses after 7 (n = 2), 8 (n = 1), and 10 (n = 1) mo	17% Within 15 mo	Axillae (48)

*Ellipses indicate data not available.

months. We performed the Minor iodine-starch test again, the results of which showed a reduced intensity of sweating. These patients received a second botulinum toxin A treatment with the same efficacy as the initial treatment and experienced no additional adverse effects or relapses of hyperhidrosis (mean follow-up, 10 months).

In interviews at the end of the follow-up period, all patients reported complete satisfaction with the local response to botulinum toxin A treatment and none reported experiencing any long-term adverse effects.

COMMENT

Many treatments for hyperhidrosis have been described, but treatment of this condition still poses a dilemma for physicians.^{16,17} Topical agents, such as aluminum chloride, may cause irritation and are only effective in the mildest cases. Iontophoresis with tap water may provide relief, especially for palmar hyperhidrosis, but the application of this treatment is relatively time-consuming and its effects temporary. The major advantage of using iontophoresis with tap water is that it is safe and easy to use at home, which provides independence for the patient.^{18,19} Systemic anticholinergic agents frequently have unacceptable adverse effects. Sympathectomy often fails to cure palmar and axillary hyperhidrosis, and complications may include surgical risks, Horner syndrome, pneumothorax, pneumonia, and compensatory hyperhidrosis after years of treatment. The positive response rate of sympathectomy as a treatment for upper-limb hyperhidrosis is about 90%, with complete satisfaction reported by about 70%; no significant differences in the outcomes of axillary and palmar hyperhidrosis have been reported.²⁰⁻²³ Recently, liposuction has been

described as an additional surgical treatment for axillary hyperhidrosis because it has none of the disadvantages of traditional excision techniques.²⁴

Physicians began using botulinum toxin A to inhibit hyperhidrosis only recently.^{4,5} Previous studies have shown that a minimal dose of 50 U of botulinum toxin A is necessary to induce anhidrosis of the axilla in healthy volunteers.⁵ To relieve palmar hyperhidrosis, 35 U of Botox¹¹ and 100 U of Botox or 120 U of Dysport⁸ were shown to be effective. To relieve axillary hyperhidrosis, 36 U of Botox,¹¹ 50 U of Botox,⁹ or 400 U of Dysport¹⁰ were shown to be effective (**Table**). The injections are easy to administer and minimally invasive. Disadvantages of this therapy include pain and burning sensations during injections and, as reported in the literature but not observed in our patients, reversible and local numbness and muscle weakness.

Our results show that intradermal, high-dose botulinum toxin A injection, 200 U per axilla, is an effective and safe therapy for axillary hyperhidrosis that results in no severe adverse effects, nor have systemic adverse effects been observed with this high-dose therapy. The dosage used is within the range of other therapeutic applications and far below the median lethal dose of 3000 U.²

Evaluation with the Minor iodine-starch test showed that each 5- to 10-U injection produced an area of anhidrosis with a diameter of 1.2 to 1.9 cm² within 6 days. This is comparable to 0.1 to 1.0 U producing a 1.0- to 1.5-cm² anhidrotic area on the forearm of a healthy volunteer.⁴

We observed a marked reduction in sweating, as demonstrated with Minor iodine-starch test results, and a significant decrease of the area of excessive sweating (from 19.27 cm² to 0.25 cm² per axilla; *P* < .001). The high-dose treatment used in the present study was as safe as

the low-dose treatment. Our findings, although preliminary, show a maximal effect for 15 months.

Only 4 relapses (17%) had occurred after 7 to 10 months. Heckmann et al²⁵ observed relapses of axillary hyperhidrosis after 3, 4, and 7 months in 25% of patients. Recently, in a review of botulinum toxin A treatment for focal hyperhidrosis, Odderson²⁶ reported an anhidrotic response lasting 2 to 8 months for axillary sweating and 13 weeks to 12 months for palmar sweating.²⁶ The high-dose treatment used in the present study decreased the relapse rate by about 50% and induced long-lasting relief for up to 15 months, findings that have not yet been reported in the literature.

When relapses occur with high-dose botulinum toxin A therapy, they occur later than relapses with low-dose therapy. Published studies report that patients showed relapses with low-dose botulinum toxin A therapy at 5.2 ± 3.3 months (mean ± SD) (n = 8), whereas patients showed relapses with high-dose therapy at 8.0 ± 1.4 months (Table).

The mechanisms responsible for the prolonged relapse-free interval for high-dose botulinum toxin A therapy are not yet clear. It may be that the functional depletion of sudorific nerves is more complete than in low-dose treatment, and reconstitution requires a longer period.^{2,3}

Since neutralizing antibodies have been described in patients treated with deep injections of botulinum toxin A, which may account for a secondary nonresponse,^{27,28} the exact intracutaneous injection technique is a crucial point. Indeed, there are no published data on the development and frequency of botulinum toxin A antibodies in patients treated for focal hyperhidrosis. Our patients who experienced relapse did respond to a second treatment as well as to initial treatment.

The available data seem to indicate a tendency toward fewer and later relapses in patients who receive high-dose botulinum toxin A therapy. Although it is too early to make final conclusions regarding the long-term outcome of our patients, our preliminary findings suggest that the use of high-dose botulinum toxin A therapy may be not only beneficial to patients but cost-effective as well.

Botulinum toxin A therapy appears to be an effective alternative to other treatments for axillary hyperhidrosis. Further studies are needed to determine the optimal dose and frequency of injections and the rate of development of neutralizing antibodies.

Accepted for publication September 28, 1999.

Corresponding author: Uwe Wollina, MD, Department of Dermatology and Allergy, University of Jena, Erfurter Strasse 35, 07740 Jena, Germany.

REFERENCES

1. Sato K, Ohtsuyama M, Samman G. Eccrine sweat gland disorders. *J Am Acad Dermatol.* 1991;24:1010-1014.
2. Brin MF. Botulinum toxin: chemistry, pharmacology, toxicity, and immunology. *Muscle Nerve Suppl.* 1997;6:S146-S168.
3. Jankovic J, Brin MF. Botulinum toxin: historical perspective and potential new indications. *Muscle Nerve Suppl.* 1997;6:S129-S137.
4. Cheshire WP. Subcutaneous botulinum toxin type A inhibits regional sweating: an individual observation. *Clin Auton Res.* 1996;6:123-126.
5. Bushara KO, Park DM, Jones JC, Schutta HS. Botulinum toxin: a possible new treatment for axillary hyperhidrosis. *Clin Exp Dermatol.* 1996;21:276-278.
6. Schneider P, Binder M, Auff E, Kittler H, Berger T, Wolff K. Double-blind trial of botulinum A toxin for the treatment of focal hyperhidrosis of the palms. *Br J Dermatol.* 1997;136:548-552.
7. Odderson IR. Axillary hyperhidrosis: treatment with botulinum toxin A. *Arch Phys Med Rehabil.* 1998;79:350-352.
8. Shelley WB, Talanin NY, Shelley ED. Botulinum toxin therapy for palmar hyperhidrosis. *J Am Acad Dermatol.* 1998;38:227-229.
9. Glogau RG. Botulinum a neurotoxin for axillary hyperhidrosis. *Dermatol Surg.* 1998;24:817-819.
10. Heckmann M, Breit S, Ceballos-Baumann A, Schaller M, Plewig G. Axilläre Hyperhidrose: Erfolgreiche Behandlung mit Botulinumtoxin-A. *Hautarzt.* 1998;49:101-103.
11. Naumann M, Hofmann U, Bergmann I, Hamm H, Tokoya KV, Reiners K. Focal hyperhidrosis: effective treatment with intracutaneous botulinum toxin. *Arch Dermatol.* 1998;134:301-304.
12. Naumann M, Bergmann I, Hofmann U, Hamm H, Reiners K. Botulinum toxin for focal hyperhidrosis: technical considerations and improvement in application. *Br J Dermatol.* 1998;139:1123-1124.
13. Greene P, Fahn S, Diamond B. Development of resistance to botulinum toxin type A in patients with torticollis. *Mov Disord.* 1994;9:213-217.
14. Zuber M, Sebald M, Bathien N, Derecondo J, Rondot P. Botulinum antibodies in dystonic patients treated with type A botulinum toxin: frequency and significance. *Neurology.* 1993;43:1715-1718.
15. Minor V. Ein neues Verfahren zu der klinischen Untersuchung der Schweißabsonderung. *Dtsch Z Nervenheilkd.* 1927;101:301-306.
16. Manusov EG, Nadeau MT. Hyperhidrosis: a management dilemma. *J Fam Pract.* 1989;28:412-415.
17. Stomam LP. Treatment of hyperhidrosis. *Dermatol Clin.* 1998;16:863-869.
18. Hölzle E, Ruzicka T. Treatment of hyperhidrosis by battery-operated iontophoretic device. *Dermatologica.* 1986;172:41-47.
19. Wollina U, Uhlemann C, Elstermann D, Köber L, Barta U. Therapie der Hyperhidrosis mittels Leitungswasser-Iontophorese: positive Effekte auf Abheilungszeit und Rezidivfreiheit bei Hand-Fuß-Ekzemen. *Hautarzt.* 1998;49:109-113.
20. Wong CW. Transthoracic video endoscopic electrocautery of sympathetic ganglia for hyperhidrosis palmaris: special reference to localization of the first and second ribs. *Surg Neurol.* 1997;47:224-249.
21. Zacherl J, Huber ER, Imhof M, Plas EG, Herbst F, Fugger R. Long-term results of 630 thoracoscopic sympathectomies for primary hyperhidrosis: the Vienna experience. *Eur J Surg Suppl.* 1998;580:43-46.
22. Moran KT, Brady MP. Surgical management of primary hyperhidrosis. *Br J Surg.* 1991;78:279-283.
23. Drott C, Gothberg G, Claes G. Endoscopic transthoracic sympathectomy: an efficient and safe method for the treatment of hyperhidrosis. *J Am Acad Dermatol.* 1995;33:78-81.
24. Payne CM, Doe PT. Liposuction for axillary hyperhidrosis. *Clin Exp Dermatol.* 1998;23:9-10.
25. Heckmann M, Schaller M, Ceballos-Baumann A, Plewig G. Follow-up of patients with axillary hyperhidrosis after botulinum toxin injection. *Arch Dermatol.* 1998;134:1298-1299.
26. Odderson IR. Hyperhidrosis treated by botulinum A exotoxin. *Dermatol Surg.* 1998;24:1237-1241.
27. Kessler KR, Skutta M, Benecke R, for the German Dystonia Study Group. Long-term treatment of cervical dystonia with botulinum toxin A: efficacy, safety, and antibody frequency. *J Neurol.* 1999;246:265-274.
28. Goschel H, Wohlfahrt K, Frevert J, Dengler R, Bigalke H. Botulinum A toxin therapy: neutralizing and nonneutralizing antibodies—therapeutic consequences. *Exp Neurol.* 1997;147:96-102.