

.....

## Thoracic Sympathectomy

*Peter B. Kestenholz, Walter Weder*

Department of Thoracic Surgery, University Hospital, Zurich, Switzerland

Oh, what clammy hand his was, as ghostly to the touch as to the sight! I rubbed mine afterward to warm it and to 'rub his off'. It was such an uncomfortable hand that when I went to my room it was still cold and wet upon my memory.

Charles Dickens in *David Copperfield*  
describing the condition of palmar hyperhidrosis in the character of Uriah Heep

The aim of the invasive treatment of hyperhidrosis is to achieve sympathectomy of the hyperhidrotic region of the body, but the indication for surgical sympathectomy has to be evaluated carefully and sympathectomy should be reserved to moderate and severe forms of primary (idiopathic) hyperhidrosis.

### Anatomical Background

Sweat glands are surrounded by sympathetic fibers. The sudomotor pathway descends from the central cortex via the hypothalamus to the medulla and from there mostly crosses to the lateral horn of the spinal cord. At a given segment of the spinal cord, preganglionic fibers (white rami) may synapse in a ganglion situated at the height of the same segment but may pass through usually to a higher level. The postganglionic fibers (gray rami) partly join the spinal nerves or accompany the segmental vessels [1]. In contrast to the ordinary sympathetic innervation, acetylcholine is the principal terminal neurotransmitter. The sympathetic chain is divided into a cervical, thoracic and lumbar portion. The thoracic chain lies anteriorly to the costovertebral junction immediately underneath the parietal pleura and in most cases in front of the intercostal vessels. Occasionally the intercostal veins may cross in front of the sympathetic chain

which is of importance for surgery. The first thoracic ganglion is normally fused with the inferior cervical ganglion, and they constitute the stellate ganglion. Each ganglion lies below the level of the corresponding intercostal nerve to which it is connected by the pre- and postganglionic fibers. The fibers of the white ramus communicans of the first thoracic nerve ascend to the superior cervical ganglion to supply sympathetic fibers to the face. Therefore an interruption may result in a decrease in facial sweating and blush. If the sympathetic chain is interrupted above the level of the first thoracic ganglion, Horner's syndrome will occur.

The highest thoracic nerve containing preganglionic fibers to the upper limb is the second one. Much variability exists of the lower limit, and preganglionic fibers from as low as the seventh or even ninth thoracic nerve may contribute to the upper limb [2]. The main ganglia responsible for the sympathetic innervation of the upper extremities are T<sub>2</sub> and T<sub>3</sub>. There is ample evidence that the second thoracic ganglion (T<sub>2</sub>) is responsible for the sympathetic innervation of the hand [1, 3-6] whereas the fourth ganglion supplies the axilla [7, 8].

An important discovery was made by Kuntz [6] in 1927. He described a nerve bypassing the second or third thoracic ganglion to the brachial plexus. Failure to destroy or excise this neural communication, which is present in as much as 10% of humans, leads to incomplete denervation of the upper extremity.

### **Nonsurgical Thoracic Sympathectomy**

Nonsurgical sympathectomy can be performed by percutaneous injection under CT guidance [9, 10] of either phenol [11] or alcohol [12]. Adler et al. [9] reported excellent short-term results (98% dry hands) although only in 6% did the effect last for more than 2 years. They observed Horner's syndrome in as high as 22% (6% temporarily) and compensatory sweating in 8% of their patients [9]. The temporary effect of medical sympathectomy associated with a very high incidence of Horner's syndrome made the technique not recommendable for the treatment of palmar hyperhidrosis. Alternative methods such as radiofrequency sympathectomy [13-16] were recommended but did not gain widespread acceptance.

### **Surgical Thoracic Sympathectomy**

The surgical approach to palmar, axillary or facial hyperhidrosis consists of various open incisions or the minimal invasive thoracoscopic technique. Most

centers worldwide have changed their policy towards the minimally invasive approach of video-assisted thoracoscopic surgery.

### *Thoracoscopic Sympathectomy*

The first thoracoscopic sympathectomy was performed by Hughes [17] in 1942 followed 2 years later by Goetz and Marr [4], but the father of thoracoscopic sympathectomy is Kux [18], who reported his extensive experience with thoracoscopic neurotomies in 1951. The real upsurge in thoracoscopic procedures has emerged in the last decade with the development of video-assisted thoracoscopic surgery.

#### *Technique*

In general two different methods are applied to destroy the sympathetic ganglia. Either the sympathetic chain is locally excised or only ablated with electrocautery or laser. Less frequently clipping of the chain is used.

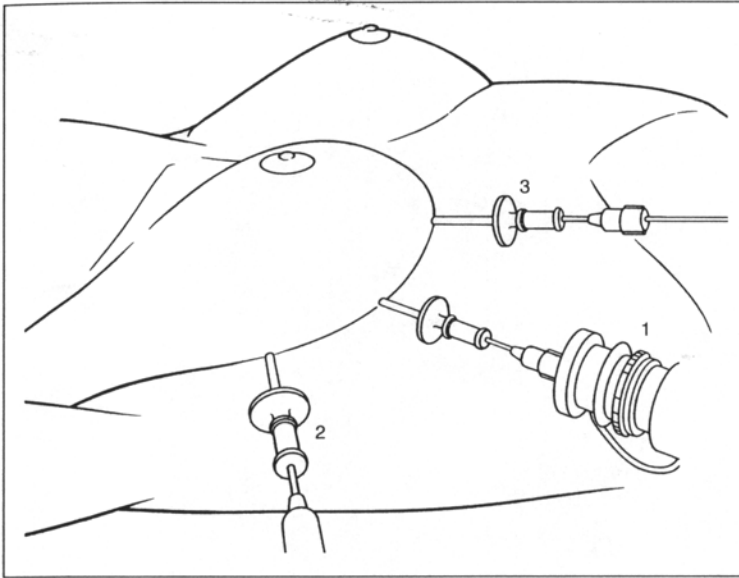
Patients are operated under general anesthesia intubated either with a double-lumen endotracheal tube for selective one-lung ventilation during surgery or rarely with a standard endotracheal tube in a semisitting position with insufflation of carbon dioxide to depress the lungs.

We recommend a double-lumen endotracheal intubation to permit a selective total collapse of the lungs. The patient is positioned supine and a 7-mm trocar for the camera, a 5-mm trocar for the electrocoagulation hook and a 2-mm trocar for a grasper are inserted in the submammary fold in the fourth intercostal space (fig. 1). The T<sub>2</sub> and T<sub>3</sub> ganglia and for axillary hyperhidrosis additionally the T<sub>4</sub> ganglion are resected and if present the Kuntz nerve is coagulated. The procedure is done bilaterally. At the end, a pleural catheter is introduced for several hours through the 5-mm trocar to evacuate pneumothorax (fig. 2-4). The patient is discharged home the following day. The operation could be performed as a same-day procedure as well. Alternatively smaller (all 2 mm) and fewer trocars may be inserted, especially if the sympathetic chain is coagulated only [19-42].

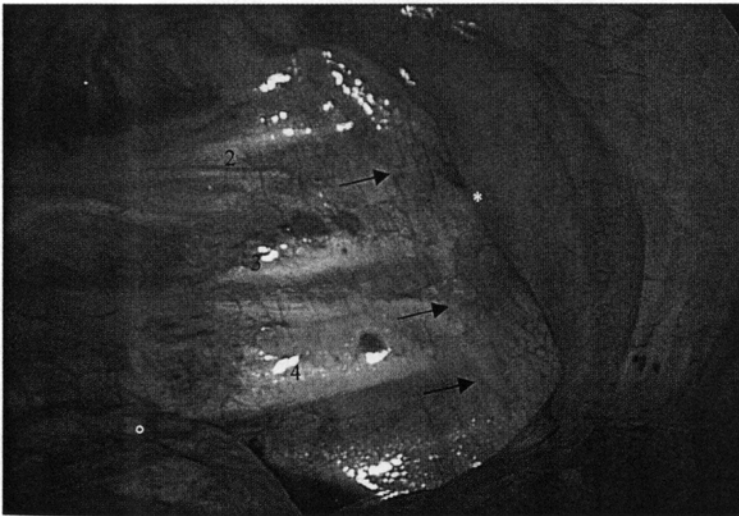
#### *The Extent of Ablation*

There is considerable controversy regarding the extent of ganglion ablation necessary to obtain denervation of the hand and the axilla. Some authors advocate an extensive denervation from T<sub>1</sub> to T<sub>6</sub> [29, 43, 44], whereas others [45-48] find ablation of the T<sub>2</sub> ganglion sufficient. Lin et al. [28] even advocate T<sub>2</sub> sympathetic block by clipping with good results.



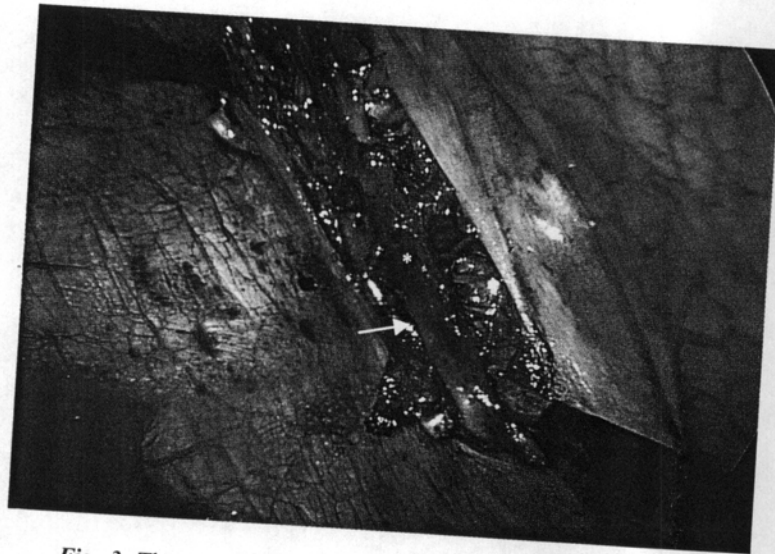

**Fig. 1.** Placement of trocars. 1 = Trocar for camera; 2, 3 = trocars for instruments (scissors, forceps and electrocoagulation hook).

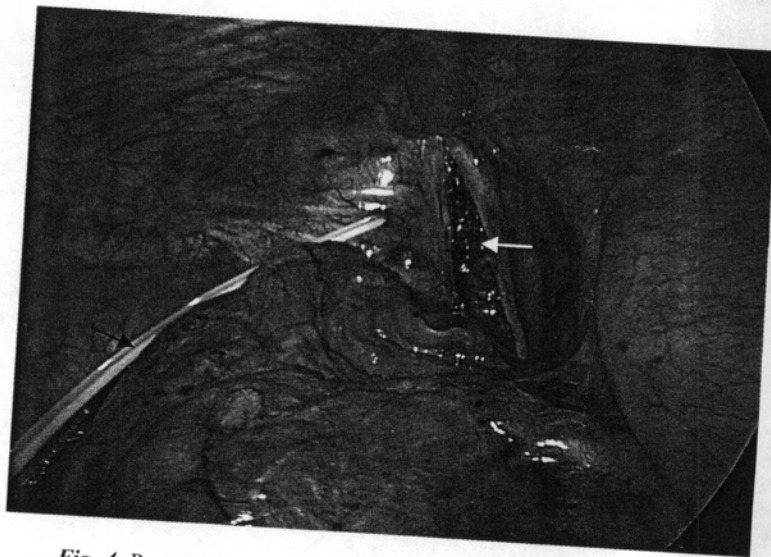


**Fig. 2.** Sympathetic chain shining through the pleura on the right side (black arrows). Second, third and fourth ribs marked by numerals. o = Collapsed right lung; \* = esophagus.





*Fig. 3.* The parietal pleura is opened longitudinally above the sympathetic chain.  
\* = Ganglion; arrow = sympathetic chain.



*Fig. 4.* Postoperative view with resected sympathetic chain including the second and third thoracic ganglia. Black arrow = Pleural catheter; white arrow = pleural incision.

The majority of surgeons [34, 36, 40] prefer to resect the T<sub>2</sub>-T<sub>3</sub> ganglia in palmar hyperhidrosis and additionally T<sub>4</sub> in axillary hyperhidrosis. Leaving the stellate ganglion untouched the risk of postoperative Horner's syndrome is negligible. The Kuntz nerve is present in approximately 10% of

**Table 1.** Success rates (%) in palmar hyperhidrosis

	Patients	Success rate	Dissatisfaction rate
Rex et al. [26], 1998	785	99.4	2.5
Lee et al. [24], 1999	930		3
Sung et al. [20], 2000	375	100	
Kao et al. [49], 1996	9,988	almost all	

patients [6, 38]. Overlooking this nerve may lead to incomplete denervation of the hand and axilla, resulting in surgical failure and early recurrence.

#### *Results of Thoracoscopic Sympathectomy*

In the last 4 years, several larger series of thoracic sympathectomy have been published [20, 24, 26, 49]. 375 patients were treated in the smallest series and 9,988 in the largest. The success rate of dry hands is as high as 98–100% with a very small recurrence rate (table 1).

#### *Complications*

The complications of thoracoscopic surgery are relatively rare. A permanent Horner's syndrome occurs in 0–0.1% [29, 30, 32, 33, 49–53] and a transient Horner's syndrome in 0–0.8% [29]. Only Zacherl et al. [25] reported an incidence of 3.8% Horner's syndrome in thoracoscopic sympathectomy, but in their series only a minority of their 630 patients were operated with video assistance and therefore the view is only limited. In a later series, they reported no Horner's syndrome after the introduction of video-assisted thoracic surgery [54]. Kopelman et al. [55] demonstrated that the incidence of Horner's syndrome depends on the experience of the surgeon. Sung et al. [20] used exclusively 2-mm instruments and reported an incidence of 0.5%.

Hemothorax and pneumothorax are extremely rare [25, 29, 30, 32, 33, 48] with an incidence of 0.3% hemothorax in the survey of Kao et al. [49] of 9,988 cases. There was no mortality in the same study.

Two cases of intraoperative cardiac arrest have been published so far [56]. The electromechanical resuscitation was successful in both patients (16-year-old boy, 21-year-old woman). Activation of cardiac sympathetic nerves is recognized as a trigger of cardiac arrhythmia, especially in patients with a long-Q-T syndrome [33].

### *Side Effects*

Compensatory sweating is the most common side effect, primarily affecting the chest, back and the thighs. It is present in a mild form in up to 84% [48], and its occurrence is unpredictable. A severe form is rare. Adar [57] reported an incidence of severe forms in around 1%. Approximately one third of the patients are moderately bothered by the side effect, and it is by far the main reason for dissatisfaction [26, 44]. Often compensatory sweating is temporary and improves with time [38, 58, 59].

The mechanism for compensatory sweating remains unclear. It seems to be more complex than simple compensation for thermoregulation [60]. The opposite event, namely decreased sweating in other parts of the body which are not anatomically denervated by upper dorsal sympathectomy, has also been reported [58, 59, 61–63]. The most important observation is concomitant reduction of perspiration of the soles, despite the fact that sympathetic innervation of the feet originates from the lumbar ganglia. It has been speculated that the hypothalamic sweat center that controls the palms, soles and axilla in some patients is distinct from the rest of the hypothalamic sweat centers and is under exclusive control of the cortex without input from the thermosensitive elements [64].

There is some evidence that a more extensive resection has a higher risk of compensatory hyperhidrosis and therefore the resection should be limited [24]. One case of sympathetic chain reconstruction with subjective relief of compensatory sweating has been reported so far [65].

Gustatory sweating is a mainly facial sweating triggered by spicy and some other specific food. Its incidence has been reported to be up to 57% [66].

Phantom sweating is a feeling of sweat pouring out of the pores of the skin without actual sweating. The incidence has been reported to be up to 48% [52]. The etiology of these two conditions is unknown as well. Most patients cope very well with them.

Neuralgia is another important sequel of sympathectomy. It consists of pain in the sympathectomized limb, appearing some time after the operation, and is presumedly temporary. Its incidence has been reported to range widely between 0 [59, 66–68] and 32% [69]. In most reports, neuralgia is not listed in the complications and therefore it does not seem to be a frequent problem.

Cardiac effects after bilateral electrocautery of the upper thoracic sympathetic ganglia ( $T_2$ – $T_4$ ) are reported on, i.e. a significant reduction of the systolic blood pressure at rest (7%) without alteration of the diastolic blood pressure. After the operation, a reduced heart rate at rest (12%) as well as during exercise and during recovery after exercise was found [70, 71].

Among the patients who had undergone thoracic sympathectomy for palmar hyperhidrosis, one third described a period of sweating in the denervated



area a few days after the operation. Immediately postoperatively they had dry hands. The period of sweating usually occurred on the third to fifth day [58, 72]. This transient hyperhidrosis following sympathectomy is probably due to a degeneration of the postganglionic fibers in the autonomous nervous system. This theory has been proven in animals. The delay of this degeneration is probably due to the length of the nerve distal to the interruption [72]. This phenomenon of transient sweating after the operation has to be explained to the patients preoperatively.

In a survey of 9,988 operated patients in Taiwan, recurrence of perspiration of the hands after sympathectomy was approximately 1% in the first year and less than 3% during the following 3 years [49].

Similar results have been reported earlier [20, 59, 66, 67, 73-75]. The reason for recurrence could either be an inadequate resection [76, 77] or a return of sympathetic tone of the limb. Nerve regeneration as shown in histological examinations of specimens obtained from a second operation could be a possible explanation [76, 78-81]. Residual sympathetic pathways traversing Skoog's ganglia, the nerve of Kuntz or white rami communicantes to the upper extremity emerging from the C<sub>8</sub> and T<sub>1</sub> spinal level could be another explanation [82-87].

#### *Open Sympathectomy*

The first sympathectomy for localized hyperhidrosis was performed in 1920 by Kotzareff [88]. During the following 50 years, different approaches have been advocated. They were used depending on the surgeon's choice. Currently all these techniques are abandoned and are of historical value only.

The supraclavicular approach was developed by Telford [85, 89]. Under general anesthesia, the patient is placed in the supine position with the shoulders elevated. A supraclavicular skin incision is made horizontally. The sternocleidomastoid muscle is split vertically and the scalenus anterior muscle is divided. Care must be taken in handling the thoracic duct and phrenic nerve, and the subclavian artery must be retracted. Finally the subpleural membrane is detached from the first rib, the pleura is displaced downward and the sympathetic chain is visible. Using this access for upper dorsal sympathectomy, dry hands were achieved in 89-100% [7, 66, 67, 74, 78, 84, 90]. Complications were frequent. A permanent Horner's syndrome occurred in up to 8%, a transient one in up to 22%. Different complications were reported such as brachial plexus damage (up to 11% transient, up to 2% mild permanent), phrenic nerve damage (up to 3.5%), transient recurrent nerve paralysis (up to 1%), thoracic duct injury (up to 1.3%), bleeding from the subclavian artery or branches (up to 3.5%) or tears of pleura with pneumothorax (up to 22%).

The *posterior approach* was first published in 1929 by Adson and Brown [91]. Through a vertical paraspinal incision, the transverse process and a part of the second and sometimes third rib were resected to expose the T<sub>1</sub>-T<sub>4</sub> ganglia. Unilateral and bilateral procedures have been performed in one stage [92]. The results are similar to those of the supraclavicular approach (92-99% dry hands) [59, 68]. Perforation of the pleura (up to 10%), hemothorax (<1%) and 1 case of dura perforation were reported.

The *axillary transpleural approach* was initiated by Schulze and Goetz and later promoted by Atkins [93]. In general anesthesia, the patient is operated in a lateral position with abducted arm. The incision is made over the second intercostal space from the pectoralis major in front to the latissimus dorsi muscle and the chest entered. After retraction of the lung, the sympathetic chain can be identified. Bilateral sympathectomy by this approach was usually performed as a staged procedure and the results are similar to those of the other surgical methods [43, 94-96].

The success rate was 93-100% dry hands. Lesioning of the long thoracic nerve was rare (1%). In 13.5%, Horner's syndrome was transient and in 1.4% permanent. 25% of the patients were dissatisfied with the cosmetic appearance of their surgical scar [43, 94-96].

The *anterior transthoracic approach* was first suggested by Goetz and Marr [4] and later by Palumbo [97]. This approach did not gain popularity for sympathectomy probably because of its poor cosmetic result.

### Conclusion

Thoracic sympathectomy offers a permanent cure of palmar and axillary hyperhidrosis. Approximately one third suffers postoperatively from compensatory hyperhidrosis of various degrees. The occurrence of compensatory hyperhidrosis is unpredictable.

The video-assisted thoracoscopic technique became the treatment of choice because of the high visibility of the surgical field and the ease with which the intrathoracic anatomy is identified, the low morbidity, short hospital stay and better cosmetic result.

### References

- 1 Sato K, Kang WH, Saga K, Sato KT: Biology of sweat glands and their disorders. I. Normal sweat gland function. *J Am Acad Dermatol* 1989;20:537-563.
- 2 Ray BS, Hinsey JC, Goehagan WA: Observations on the distribution of the sympathetic nerves to the pupil and upper extremity as determined by stimulation of the anterior roots in man. *Ann Surg* 1943;118:647-655.

- 3 Hyndman OR, Wolkin J: Sympathectomy of the upper extremity: Evidence that only the second dorsal ganglion need be removed for complete sympathectomy. *Arch Surg* 1942;45:145-155.
- 4 Goetz RH, Marr JAS: The importance of the second thoracic ganglion for sympathetic supply of the upper extremities with a description of two new approaches for its removal. *Clin Proc* 1944;3:102-114.
- 5 O'Riordain DS, Maher M, Waldron DJ, O'Donovan B, Brady MP: Limiting the anatomic extent of upper thoracic sympathectomy for primary palmar hyperhidrosis. *Surg Gynecol Obstet* 1993;176:151-154.
- 6 Kuntz A: Distribution of the sympathetic rami to the brachial plexus. *Arch Surg* 1927;15:871-877.
- 7 Greenhalgh RM, Rosengarten DS, Martin P: Role of sympathectomy for hyperhidrosis. *Br Med J* 1971;i:332-334.
- 8 Malone PS, Cameron AE, Rennie JA: The surgical treatment of upper limb hyperhidrosis. *Br J Dermatol* 1986;115:81-84.
- 9 Adler OB, Engel A, Rosenberger A, Dondelinger R: Palmar hyperhidrosis CT guided chemical percutaneous thoracic sympathectomy. *Rofo Fortschr Geb Röntgenstr Neuen Bildgeb Verfahr* 1990;153:400-403.
- 10 Dondelinger RF, Kurdziel JC: Percutaneous phenol block of the upper thoracic sympathetic chain with computed tomography guidance: A new technique. *Acta Radiol* 1987;28:511-515.
- 11 Haxton HA: Chemical sympathectomy. *Br Med J* 1949;1:1026-1028.
- 12 Levine IM, Harris OJ: Chemical sympathectomy: New approach to treatment of localized hyperhidrosis. *Arch Dermatol Syphilol* 1955;71:226-230.
- 13 Wilkinson HA: Percutaneous radiofrequency upper thoracic sympathectomy: A new technique. *Neurosurgery* 1984;15:811-814.
- 14 Wilkinson HA: Radiofrequency percutaneous upper-thoracic sympathectomy: Technique and review of indications. *N Engl J Med* 1984;311:34-36.
- 15 Wilkinson HA: Percutaneous radiofrequency upper thoracic sympathectomy. *Neurosurgery* 1996;38:715-725.
- 16 Chuang KS, Liou NH, Liu JC: New stereotactic technique for percutaneous thermocoagulation upper thoracic ganglionectomy in cases of palmar hyperhidrosis. *Neurosurgery* 1988;22:600-604.
- 17 Hughes J: Endothoracic sympathectomy. *Proc R Soc Med* 1942;35:585-586.
- 18 Kux E: The endoscopic approach to the vegetative nervous system and its therapeutic possibilities. *Dis Chest* 1951;20:139-147.
- 19 Yamamoto H, Kanehira A, Kawamura M, Okada M, Ohkita Y: Needleoscopic surgery for palmar hyperhidrosis. *J Thorac Cardiovasc Surg* 2000;120:276-279.
- 20 Sung SW, Kim YT, Kim JH: Ultra-thin needle thoracoscopic surgery for hyperhidrosis with excellent cosmetic effects. *Eur J Cardiothorac Surg* 2000;17:691-696.
- 21 Yim AP, Liu HP, Lee TW, Wan S, Arifi AA: 'Needlescopic' video-assisted thoracic surgery for palmar hyperhidrosis. *Eur J Cardiothorac Surg* 2000;17:697-701.
- 22 Goh PM, Cheah WK, De Costa M, Sim EK: Needleoscopic thoracic sympathectomy: Treatment for palmar hyperhidrosis. *Ann Thorac Surg* 2000;70:240-242.
- 23 Lee DY, Yoon YH, Shin HK, Kim HK, Hong YJ: Needle thoracic sympathectomy for essential hyperhidrosis: Intermediate-term follow-up. *Ann Thorac Surg* 2000;69:251-253.
- 24 Lee DY, Hong YJ, Shin HK: Thoracoscopic sympathetic surgery for hyperhidrosis. *Yonsei Med J* 1999;40:589-595.
- 25 Zacherl J, Huber ER, Imhof M, Plas EG, Herbst F, Fugger R: Long-term results of 630 thoracoscopic sympathectomies for primary hyperhidrosis: The Vienna experience. *Eur J Surg Suppl* 1998;580:43-46.
- 26 Rex LO, Drott C, Claes G, Gothberg G, Dalman P: The Boras experience of endoscopic thoracic sympathectomy for palmar, axillary, facial hyperhidrosis and facial blushing. *Eur J Surg Suppl* 1998;580:23-26.
- 27 Krasna MJ, Demmy TL, McKenna RJ, Mack MJ: Thoracoscopic sympathectomy: The US experience. *Eur J Surg Suppl* 1998;580:19-21.