

---

## Ross syndrome: Treatment of segmental compensatory hyperhidrosis by a modified iontophoretic device

Stephen Reinauer, MD, Gunnar Schauf, and Erhard Hölzle, MD *Düsseldorf, Germany*

In 1958 the triad of tonic pupils, areflexia (Holmes-Adie syndrome), and hypohidrosis was first described by Ross. Since then more than 15 patients with a similar condition have been described. Two cases with the typical triad in combination with associated autonomic dysfunctions are presented. Subjectively, the most disturbing symptom is segmental compensatory hyperhidrosis, which results from widespread hypohidrosis or anhidrosis. For treatment of hyperhidrosis, tap water iontophoresis was applied using a modified technique with special electrodes. In both patients the hyperhidrosis was relieved after 20 treatments. (J AM ACAD DERMATOL 1993;28:308-12.)

Many conditions can be associated with hypohidrosis or anhidrosis. These include dysfunctions of the endocrine system,<sup>1</sup> drugs, infections,<sup>2</sup> tropical anhidrotic asthenia,<sup>2</sup> genodermatoses,<sup>3</sup> mechanical obstruction of the acrosyringium caused by inflammatory dermatoses,<sup>2</sup> neurologic disorders,<sup>3</sup> dehydration, and idiopathic anhidrosis.<sup>4</sup>

The association of a unilateral tonic pupil and areflexia (Holmes-Adie syndrome) with segmental

progressive hypohidrosis was first described by Ross in 1958.<sup>2</sup>

The hypohidrosis is usually not perceived by the patient. It is the compensatory segmental hyperhidrosis, which results from progressive failure of most dermal segments, that is finally noticed.

Two patients with typical symptoms of Ross syndrome are described. Both also had associated vegetative dysfunctions of several organ systems.

### CASE REPORTS

#### Case 1

In 1980 a 45-year-old woman had bilateral tonic pupils associated with disturbed accommodation and adaptation. Since 1985 she has had hyperhidrosis of the left

From the Department of Dermatology, Heinrich-Heine-University Düsseldorf.

Reprints not available.

Copyright © 1993 by the American Academy of Dermatology.

0190-9622/93 \$1.00 + .10 16/4/41469

lumbar segments L2 and L3, which has resulted in wet clothes, hypothermia of the skin, and psychosocial problems. Additional problems included recurrent peptic ulcers, reflux esophagitis, palpitation, stenocardia, orthostatic hypotonia, heat intolerance, and hot flushes during the summer. Her medications included bisoprolol fumarate, nifedipine, triamterene, and hydrochlorothiazide.

Physical examination revealed hyperhidrosis in the lumbar segments L2 and L3 of the left leg and hypohidrosis in the remaining segments. This was verified by the starch iodine technique and measurements of evaporative water loss from the skin surface (Fig. 1, A) with the Evaporimeter EP1 apparatus (Servomed, Kinna, Sweden).

Punch biopsy specimens were obtained from hyperhidrotic and hypohidrotic areas. The hypohidrotic area (right inguinal region) showed structurally normal eccrine sweat glands with accumulation of glycogen in secretory cells as a sign of inactivity. Occasionally, periodic acid-schiff positive, diastase-resistant eosinophilic material was present in the acini of the glands. The hyperhidrotic area (left inguinal region) showed normal eccrine sweat glands.

There was a normal piloerection to a low temperature stimulus in hyperhidrotic and hypohidrotic areas.

Findings of chest x-ray film and magnetic resonance imaging of the lumbar segments were normal. All deep tendon reflexes were absent. The electrically induced, monosynaptic, proprioceptive reflex (H-reflex), which shows a polyphasic pattern with a higher threshold and lower amplitude in patients who have Holmes-Adie syndrome, was normal.

A marked difference was observed in the diameter of the pupils (right, 4.5 mm, and left, 3.0 mm). The pupils did not react to light and responded weakly to convergence. Accommodation time was increased.

## Case 2

A 45-year-old woman had segmental hyperhidrosis of her right side. She had sepsis and meningitis in early infancy. A cranial fracture with cerebral trauma at the age of 7 years resulted in developmental retardation and delayed onset of puberty. In 1977 she received a left hip joint prosthesis, which was followed by paresis of the left sciatic nerve.

Since 1978 the patient has had hyperhidrosis of the thoracic segments T10, T11, and T12. In addition, she had chronic respiratory tract infections, an irritable colon, orthostatic hypotonia, heat-induced flushes, nausea during the summer, palpitation of the heart, migraine headaches, dry skin, and psychosocial problems. She has been aware of tonic pupils with sensitivity to light since 1981.

Physical examination revealed hyperhidrosis and hy-

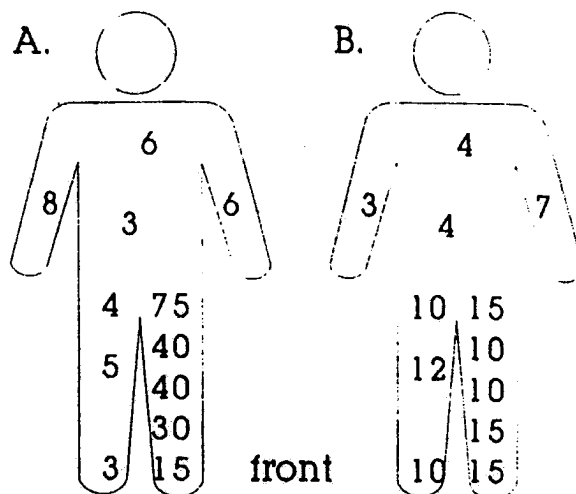


Fig. 1. Case 1. Measurements of evaporative water loss (expressed as grams per square meter per hour) from the skin surface, before (A) and after (B) treatment with use of a modified technique of tap water iontophoresis. Room temperature was 20° C.

popigmentation of the thoracic segments T10, T11, and T12, in contrast to hypohidrosis or anhidrosis of the remaining segments, which was verified by the starch iodine technique (Fig. 2, A) and measurements of skin surface evaporation. Xeroderma with eczema craquèle was present in the hypohidrotic segments. Dermographism, skin temperature, and piloerection were normal in hypohidrotic areas. The pupils were irregular and reacted only weakly to light stimulus and to convergence. All deep tendon reflexes were absent. The H-reflex was normal.

## Treatment

Tap water iontophoresis with modified electrodes was initiated. The Hidrex H1p apparatus (Schauf, Wuppertal, Germany), which is operated by a rechargeable energy source, was used.<sup>5</sup>

For treatment of the hyperhidrotic segments of the first patient's leg, a special applicator was prepared. The applicator consisted of two halves of Dynacast plastic bowls (Brown, Smith and Nephew GmbH, Spangenberg, Germany), which reached from the inguinal region down to the malleoli. The lower bowl served as an anode, and the upper bowl served as a cathode; both bowls were coated with wet sponges (Fig. 3).

After 3 weeks of daily treatments at a direct current of 25 mA and 15 V for 20 minutes, sweating was reduced to normal, as verified by the starch iodine technique and measurements of evaporative skin water loss (Fig. 1, B). For maintenance therapy, tap water iontophoresis was carried out once weekly.

A semicircle applicator of Dynacast plastic was molded onto the skin of the right thoracic segments T10, T11, and

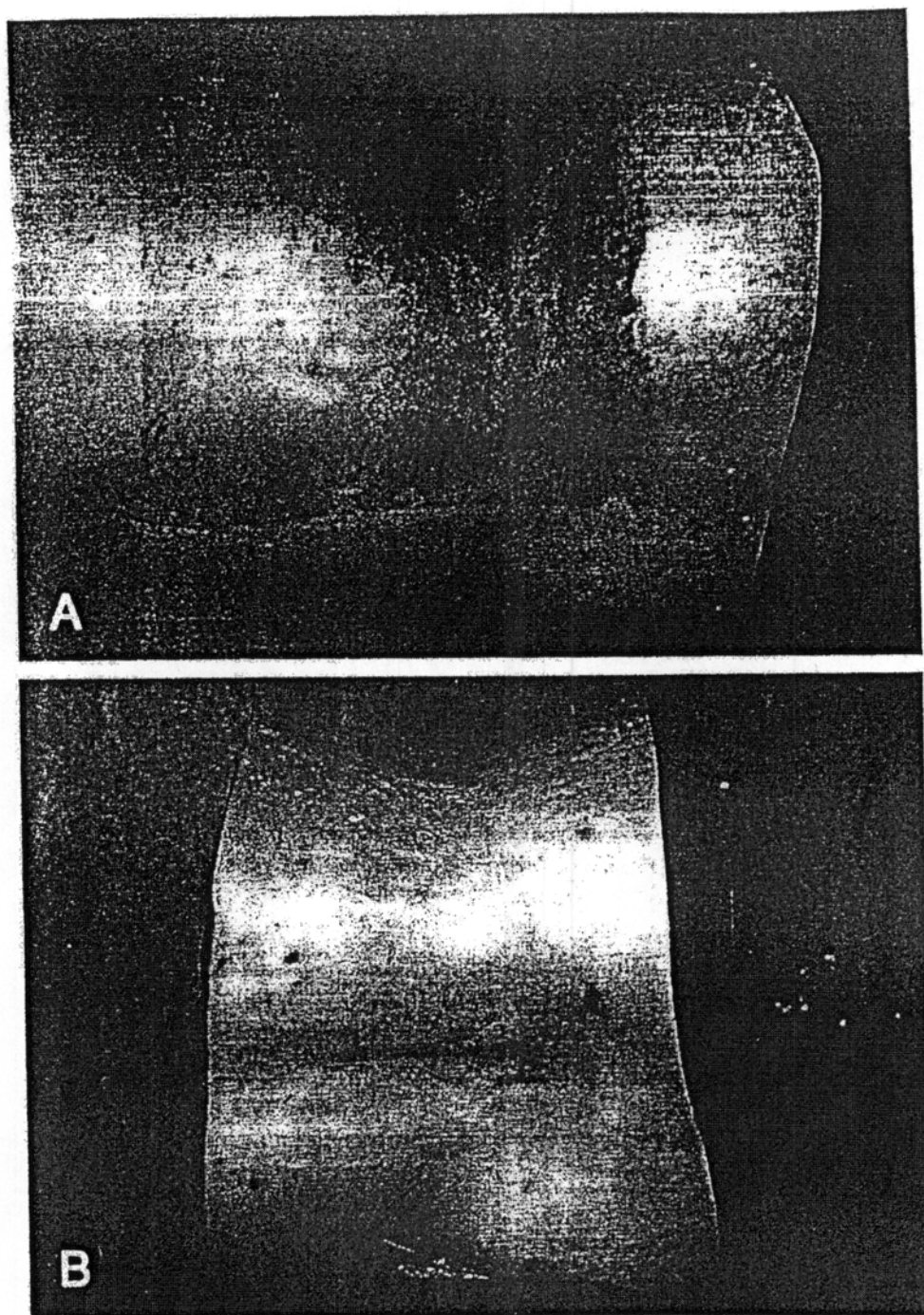


Fig. 2. Case 2. Hyperhidrotic thoracic segments T10, T11, and T12, shown by the starch iodine technique, before (A) and after (B) treatment with tap water iontophoresis.

T12 of the second patient. Iontophoresis with the Hidrex H1p was carried out three times per week at a direct current of 25 mA and 15 V. After 20 treatments in 80 days, sweating of the right thoracic segments T10, T11, and T12 was normal, as shown by colorimetric (Fig. 2, B) and hygrometric methods.

#### DISCUSSION

Ross syndrome was first described in 1958. Ross, however, believed that widespread segmental hypo-

hidrosis was accidentally associated with the Holmes-Adie syndrome.<sup>2</sup> Since then more than 15 similar cases have been reported,<sup>2,6-11</sup> and the triad of tonic pupils, areflexia, and hypohidrosis or anhidrosis was termed Ross syndrome. The disorder has no predilection for age, race, or sex.<sup>8</sup>

Because piloerection and vasomotor control in patients with Ross syndrome are normal, the sympathetic dysfunction involves sudomotor fibers exclusively. Hypohidrosis or anhidrosis is usually not

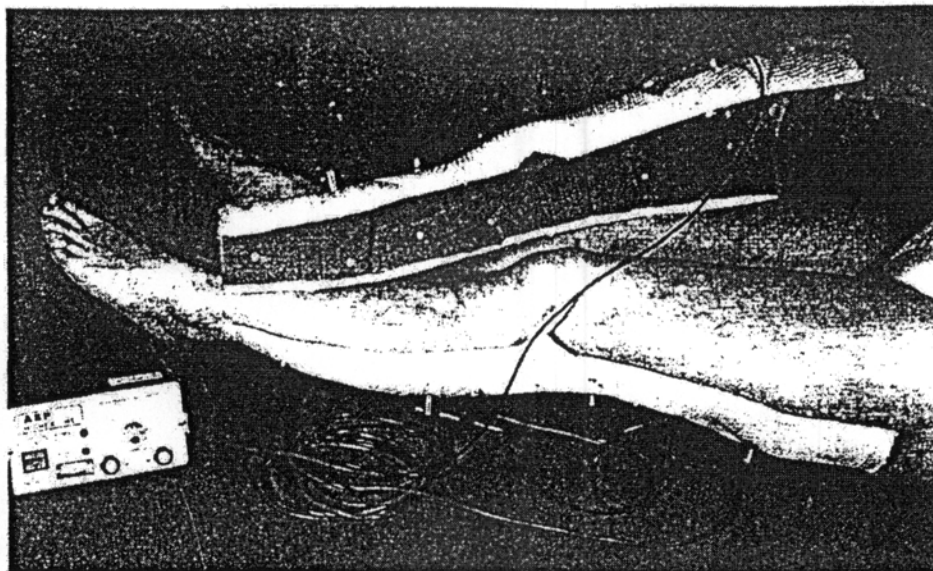


Fig. 3. Case 1. Iontophoresis applicator.

perceived by the patient early in the course of the disease. Dysfunction of sweat glands becomes conspicuous when compensatory segmental hyperhidrosis of the functionally intact segments<sup>2,9</sup> occurs. Compensatory sweating associated with heat intolerance is an attempt to overcome the impaired thermoregulation.

Signs of autonomic dysfunction such as orthostatic hypotension, palpitation of the heart, vagovagal syncope, dyspnea, headache, reflux esophagitis, an irritable colon, and psychiatric disorders can be associated with the triad of symptoms.<sup>6,9,12</sup> These signs were present in both of our patients. It is believed that these associated autonomous disturbances of various organ systems are a characteristic feature of the symptom complex.

The pathogenesis of Ross syndrome is unknown. Structural changes of sudomotor fibers and the eccrine glands, except for signs of inactivity, have not been observed.<sup>2,9</sup> There are no differences in the electrolyte content of sweat from hypohidrotic or hyperhidrotic areas.<sup>8</sup> In the literature<sup>2,8,9,13</sup> multiple neuropathies of the autonomic nervous system or a failure in the synthesis or release of neurotransmitters<sup>9</sup> have been suggested as hypothetical mechanisms.

One approach to the symptomatic relief of the segmental hyperhidrosis is tap water iontophoresis. It is effective and has only minimal side effects in patients with hyperhidrosis of palms or soles.<sup>5</sup> Repeat treatments produce a reversible inhibition of hyperfunction of sweat glands.

The method was modified by the design of custom-made electrodes for the hyperhidrotic skin

areas. During treatment, amperage was maintained just below the threshold for discomfort. After 20 treatments, sufficient suppression of hyperhidrosis was achieved in both of our patients.

No progression in heat intolerance was seen in either patient, because compensatory hyperhidrosis is virtually ineffective in thermoregulation. With the aid of an apparatus suitable for home treatment, the patients were able to avoid frequent visits to the clinic. As with tap water iontophoresis of the palms and soles,<sup>5</sup> maintenance treatment once weekly was required. Side effects were not observed.

#### REFERENCES

1. Fealey RD, Low PA, Thomas JE. Thermoregulatory sweating abnormalities in diabetes mellitus. *Mayo Clin Proc* 1989;64:617-28.
2. Ross AT. Progressive selective sudomotor denervation. *Neurology* 1958;8:809-17.
3. Sato K, Kang WH, Saga K, et al. Biology of sweat glands and their disorders. *J AM ACAD DERMATOL* 1989;20:713-26.
4. Murakami K, Sobue G, Teraos S, et al. Acquired idiopathic generalized anhidrosis: a distinctive clinical syndrome. *J Neurol* 1988;235:428-31.
5. Hölzle E, Alberti N. Long term efficacy and side effects of tap water iontophoresis of palmoplantar hyperhidrosis: the usefulness of home therapy. *Dermatologica* 1987;175:126-35.
6. Bardin RH, Schmutz JL, Cuny JF, et al. Le syndrome de Ross: a propos d'une observation. *Ann Dermatol Venerol* 1990;117:113-4.
7. Drummond PD, Edis RH. Loss of facial sweating and flushing in Holmes-Adie syndrome. *Neurology* 1990;40:847-9.
8. Esterly NB, Cantolino SJ, Alter BP, et al. Pupillotonia, hyporeflexia, and segmental hypohidrosis: autonomic dysfunction in a child. *J Pediatr* 1968;73:852-9.
9. Frosch PJ, Hartschuh W, Weihe E, et al. Pupillotonia with areflexia and segmental hypohidrosis (Ross' syndrome). In

Wilkinson DS, Mascaró JM, Orfanos CE, et al., eds. *Clinical dermatology: the CMD case collection/17th World Congress of Dermatology*, Berlin. New York: Schattauer, 1987:189-191.

10. Heath PD, Moss C, Cartledge NEF. Ross syndrome and skin changes. *Neurology* 1982;32:1041-2.
11. Spector RH, Bachmann DL. Bilateral Adie's tonic pupil

with anhidrosis and hyperthermia. *Arch Neurol* 1984; 41:342-3.

12. Hedges TR, Gerner EW. Ross' syndrome (tonic pupil plus). *Br J Ophthalmol* 1975;59:387-91.
  13. Hallermann W. Schweißsekretionsstörung beim Adie-Syndrom: Eine Neuropathia multiplex der peripheren autonomen Nerven? *Akt Neurol* 1990;17:179-83.
-